PARS SUPRAMESOCOLICA

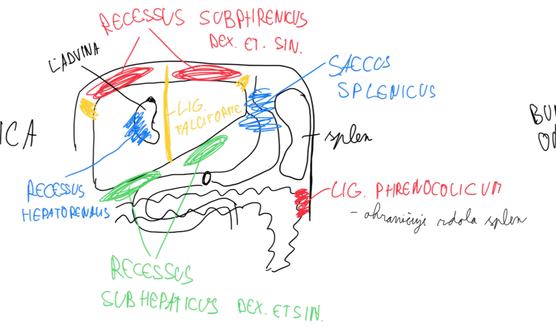

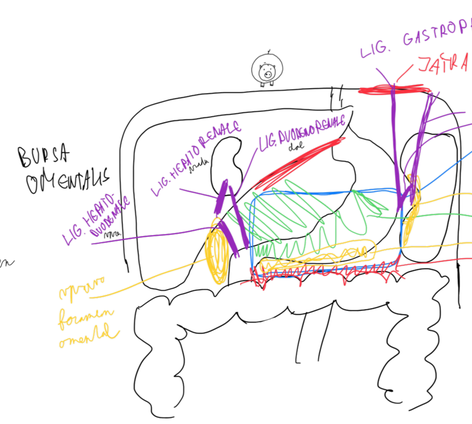

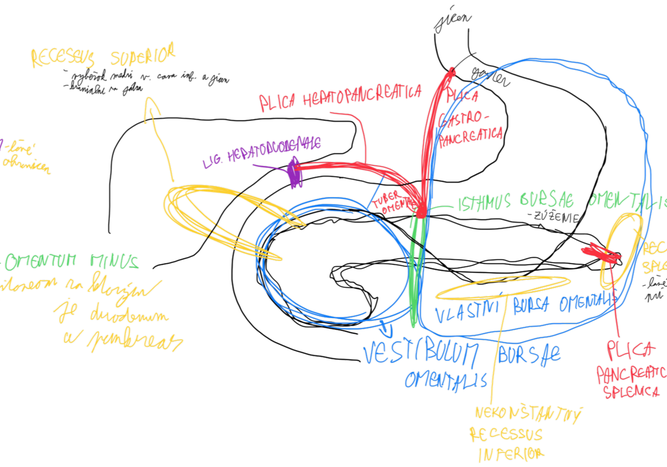

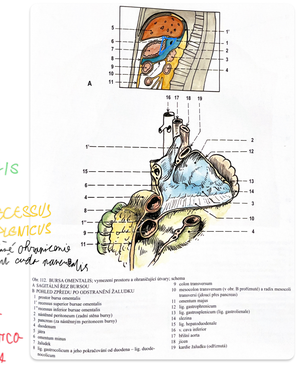

Obr. 112. BURSA OMENTALIS; vyznačení prostoru a dávnejšiej úvary; schema
A SAGITÁLNÍ ŘEZ BURSOU
B POHLED ZPŘEDU PO ODSTRANĚNÍ ZALUDKU

1 prostor bursa omentalis
2 recessus superior bursae omentalis
3 recessus inferior bursae omentalis
4 plica hepatopancreatica (radix mesoduodeni pars descens (ex parte) duodeni)
5 duodenum
6 jícen
7 recessus minus
8 fundus
9 lig. gastrocolicum a jeho pokračování od duodena - lig. duodenocolicum
10 colon transversum
11 mesocolon transversum (v obr. B profilovaná s radix mesocoli transversi (jdoucí přes pancreas))
12 pancreas
13 lig. gastrophrenicum
14 lig. gastrosplenicum (lig. gastrolienale)
15 slezina
16 lig. hepatoduodenale
17 vena portae hepatis
18 tetiní arteria
19 pečeň
20 kapsle Glissonova (adventitia)

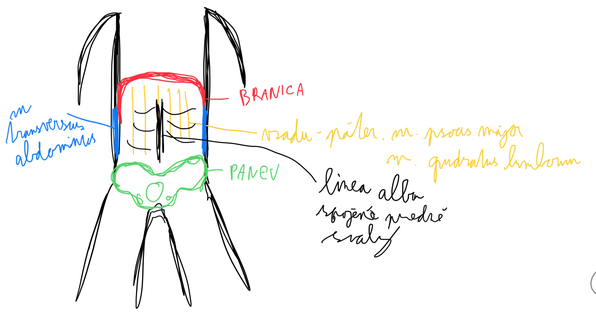

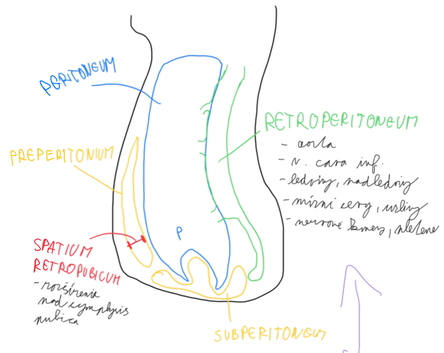

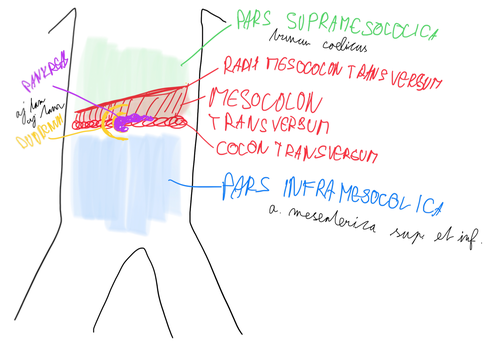

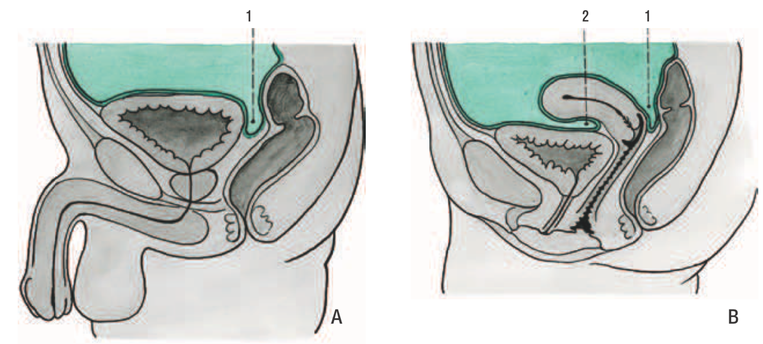

Obr. 205. ZÁHYBY PERITONEA PŘI PÁNEVNÍCH ORGÁNECH; schema

A MEDIÁNNÍ ŘEZ PÁNVÍ MUŽE	B MEDIÁNNÍ ŘEZ PÁNVÍ ŽENY
1 excavatio rectovesicalis	1 excavatio rectouterina
	2 excavatio vesicouterina

PERITONEUM → vyskytla vrstva bunieč. diferencia

PARIETALE — VISCERALE

MESENTERIA

TUNICA SEROSA — 1 v. D. EPI = MESOTHEL

TELA SUBSEROSA

duodenum a pankreas na skúške u Laichmana v žiadnom, ale žiadnom prípade nie sú sekundárne retroperitoneálne, ale sú **VRASTENÉ DO DORZÁLNEHO PARIETÁLNEHO PERITONEA**, do ktorého sú zatlačené agresívnym rastom jater a pankreas je od retroperitoneálne prebiehajúcej aorty oddelený retropankreatickou Treitzovou membránou

PANKREAS A DUODENUM SÚ VLOŽENÉ AŽ DO VŠÁDE

PARS INFRAMESOCOLICA

MIESTA KDE SÚ RECESSUSI, FOSSAE ET PLICAE

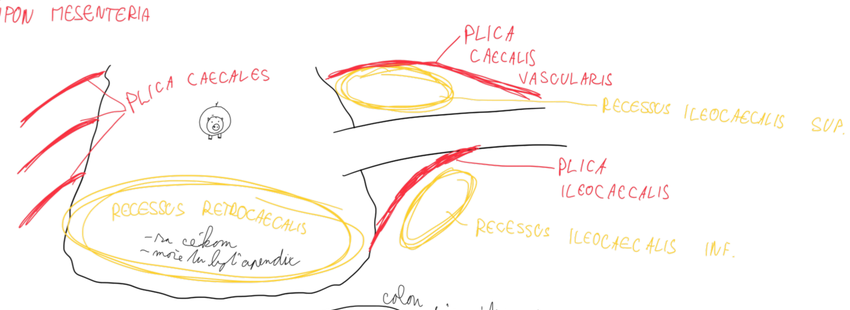

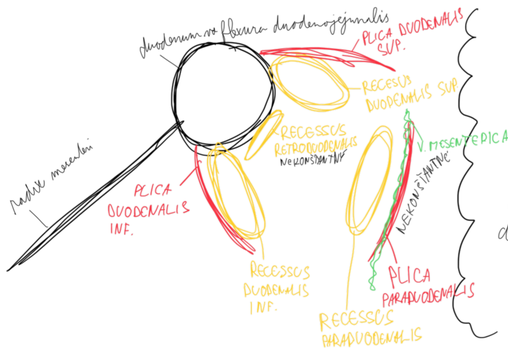

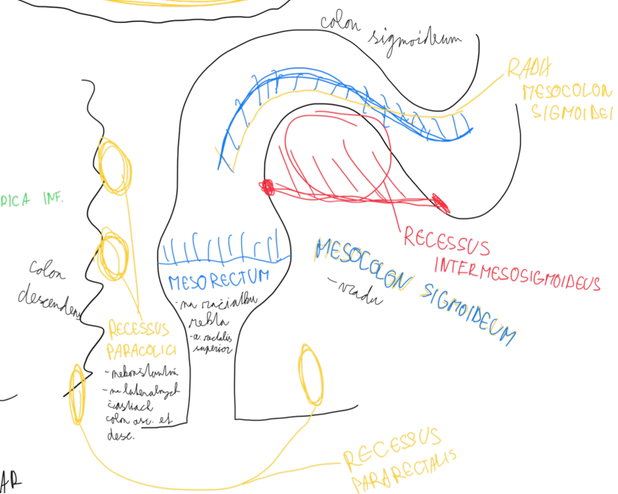

ZÁVESY ORGÁNU

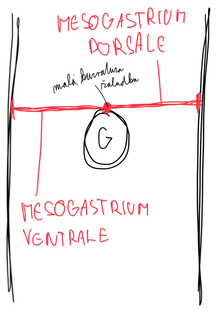
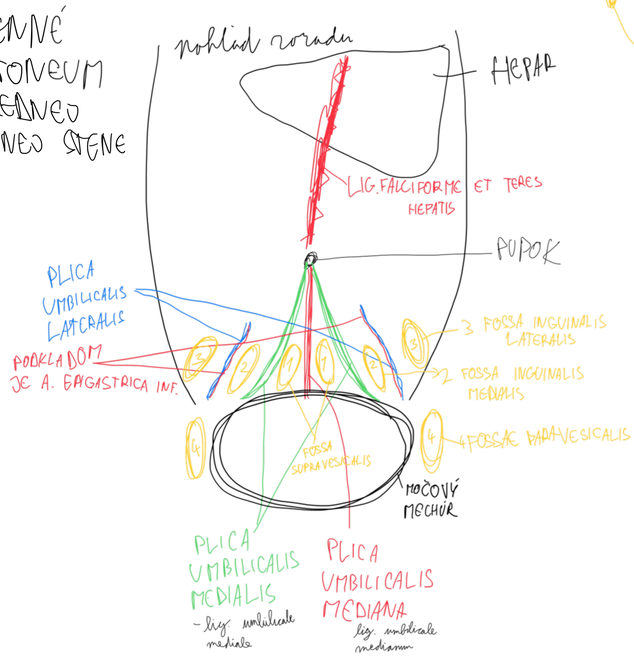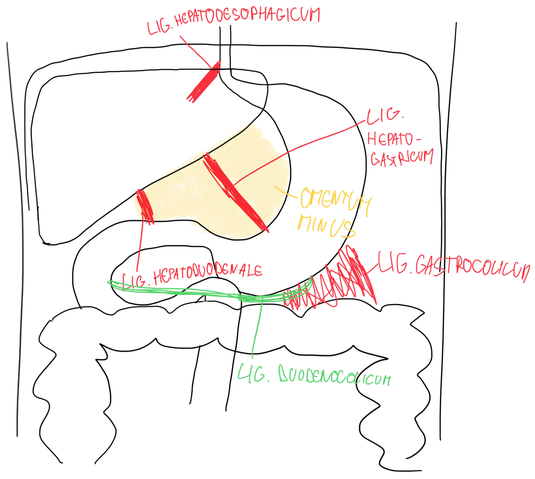
NASTENNÉ PERITONEUM NA PREDNEJ BRUŠNEJ STENE